

20

Locomotion and Movement

TOPIC 1

Skeletal Muscle and its Contraction

01 During muscular contraction, which of the following events occur?

[NEET 2021]

- I. 'H' zone disappears
- II. 'A' band widens
- III. 'I' band reduces in width
- IV. Myosine hydrolyses ATP, releasing the ADP and Pi
- V. Z-lines attached to actins are pulled inwards.

Choose the correct answer from the options given below.

- (a) I, III, IV and V
- (b) I, II, III and IV
- (c) II, III, IV and V
- (d) II, IV, V and I

Ans. (a)

Statements I, III, IV, and V are correct and statement II is incorrect and can be corrected as During muscular contraction by utilising energy from ATP hydrolysis the myosin head binds to the exposed active sites on actins to form a cross bridge.

This pulls the attached actin filaments towards the center of A band. This movement constricts 'A' band.

02 Calcium is important in skeletal muscle contraction because it

[NEET 2018]

- (a) detaches the myosin head from the actin filament
- (b) activates the myosin ATPase by binding to it

- (c) binds to troponin to remove the masking of active sites on actin for myosin
- (d) prevents the formation of bonds between the myosin cross bridges and the actin filament

Ans. (c)

Calcium plays a key regulatory role in muscle contraction. Ca^{2+} ions bind to troponin and changes its shape and position. This in turn, alter the shape and position of tropomyosin and hence, the active sites on F-actin are exposed. Due to this, myosin cross-bridges are able to bind to these active sites and muscle contraction occurs.

03 Lack of relaxation between successive stimuli in sustained muscle contraction is known as

[NEET 2016, Phase I]

- (a) fatigue
- (b) tetanus
- (c) tonus
- (d) spasm

Ans. (b)

Sustained muscle contraction due to repeated stimulus is known as tetanus. This results due to muscle fatigue.

04 Name the ion responsible for unmasking of active sites for myosin for cross-bridge activity during muscle contraction.

[NEET 2016, Phase II]

- (a) Calcium
- (b) Magnesium
- (c) Sodium
- (d) Potassium

Ans. (a)

Ca^{++} ions bind with T_p unit of troponin which is responsible for masking of active sites for myosin through tropomyosin. The event initiates cross-bridge activity during muscle contraction mechanism.

05 Smooth muscles are

[NEET 2016, Phase II]

- (a) involuntary, fusiform, non-striated
- (b) voluntary, multinucleate, cylindrical
- (c) involuntary, cylindrical, striated
- (d) voluntary, spindle-shaped, uninucleate

Ans. (a)

Smooth muscles are involuntary, fusiform and non-striated.

These muscles are located in the inner walls of hollow visceral organs of the body like alimentary canal, reproductive tract, etc.

They do not exhibit any striation and are smooth in appearance. Their activities are under autonomic and hormonal control and thus they are also known as involuntary muscles.

Hence, option (a) is correct.

06 The H-zone in the skeletal muscle fibre is due to

[NEET 2013]

- (a) the absence of myofibrils in the central portion of A-band
- (b) the central gap between myosin filaments in the A-band
- (c) the central gap between actin filaments extending through myosin filaments in the A-band
- (d) extension of myosin filaments in the central portion of the A-band

Ans. (c)

H-zone in skeletal muscle is due to the central gap between actin filaments extending through myosin filaments in the A-band. Alternate arrangement of dark and light bands gives the striated appearance to a skeletal muscle. At the centre of A-band, a comparatively less dark zone called H-zone is present.

In the centre of H-zone, M-line is present, formed by the threads that connect the myofilaments.

- 07** Which one of the following is the correct pairing of a body part and the kind of muscle tissue that moves it? [CBSE AIPMT 2009]

- (a) Heart wall — Involuntary unstriated muscle
(b) Biceps of upper arm — Smooth muscle fibres
(c) Abdominal wall — Smooth muscle
(d) Iris — Involuntary smooth muscle

Ans. (d)

Smooth muscles are plain, non-striated, involuntary or unstriated muscles due to the absence of striations. These occur in the walls of hollow internal organs, in capsules of lymph glands, spleen, etc., in iris and ciliary body of eyes, skin dermis, penis and other accessory genitalia, etc.

- 08** The contractile protein of skeletal muscle involving ATPase activity is [CBSE AIPMT 2006]

- (a) myosin (b) a-actinin
(c) troponin (d) tropomyosin

Ans. (a)

The kinesin, myosin and dynein proteins of skeletal muscle involve ATPase activity. This activity cause the contraction of skeletal muscles, propelling action of cilia and flagella and the intracellular transport of organelles.

- 09** ATPase enzyme needed for muscle contraction is located in [CBSE AIPMT 2004]

- (a) actinin (b) troponin
(c) myosin (d) actin

Ans. (c)

During muscular contraction myosin cross bridges heads. Myosin is not only an actin binding protein, it is also an ATPase (an enzyme) which is activated by Ca^{2+} and Mg^{2+} ions. Hence, ATPase enzyme is located in myosin.

- 10** Which statement is correct for muscle contraction? [CBSE AIPMT 2001]

- (a) Length of H-zone decrease
(b) Length of A-band remains constant
(c) Length of I-band increases
(d) Length of two Z-line increases

Ans. (b)

When Ca^{+} ions combine with troponin then in consequence muscle contraction will initiates.

During contraction, the Z-lines come closer together and the sarcomere becomes shorter. The length of A-band remains constant. I-bands shortens and H-zone narrows.

- 11** What is sarcomere? [CBSE AIPMT 2001]

- (a) Part between two H-lines
(b) Part between two A-lines
(c) Part between two I-bands
(d) Part between two Z-lines

Ans. (d)

Huxley reported the fine structure of striated muscle fibre or myofibril. Each myofibril is made up of A-bands (dark band anisotropic) and I-bands = isotropic (light bands isotropic). These two bands are made up of myosin and actin filament respectively. Each I-band is divided into two equal halves by a thin, fibrous and transverse zig-zag partition, called Z-band or Z-disc or Krause's membrane.

The part of the myofibril between two successive Z-lines functions as a contractile unit called sarcomere.

- 12** The functional unit of contractile system in striated muscle is [CBSE AIPMT 1998]

- (a) myofibril (b) sarcomere
(c) Z-lines (d) cross bridges

Ans. (b)

Skeletal muscle is also called striated muscle because the regular arrangement of the myofilaments creates as repeating pattern of light and dark bands. Each repeating unit is a **sarcomere**, the basic functional unit of the muscle.

- 13** Which of the following is the contractile protein of a muscle? [CBSE AIPMT 1998]

- (a) Myosin (b) Tropomyosin
(c) Actin (d) Tubulin

Ans. (a)

Myosin-II, a two-headed tailed variety of myosin is involved in muscle contraction.

- 14** Which ion is essential for muscle contraction? [CBSE AIPMT 1994]

- (a) Na (b) K (c) Ca (d) Cl

Ans. (c)

Calcium is an essential element required for the contraction of muscles. Release of calcium ions from sarcoplasmic reticulum trigger the muscle contraction process. In fact, calcium ions and ATP, actin and myosin interact forming actomyosin, which causes the muscles to contract.

- 15** Intercostal muscles occur in [CBSE AIPMT 1988]

- (a) abdomen (b) thigh
(c) ribs (d) diaphragm

Ans. (c)

Intercostal muscles, i.e. internal intercostal and external intercostal are attached with the ribs, these are the main muscles for normal quite breathing. External intercostal muscle and diaphragm contract during inspiration and relax during expiration.

TOPIC 2 Skeletal System

- 16** Match the List I with List II. [NEET 2021]

| List I | List II |
|---------------------|-------------------------|
| A. Scapula | 1. Cartilaginous joints |
| B. Cranium | 2. Flat bone |
| C. Sternum | 3. Fibrous joints |
| D. Vertebral column | 4. Triangular flat bone |

Choose the correct answer from the options given below.

- A B C D
(a) 1 3 2 4
(b) 2 3 4 1
(c) 4 2 3 1
(d) 4 3 2 1

Ans. (d)

(A)-(4), (B)-(3), (C)-(2), (D)-(1)

Scapula It is a flat, triangular shaped bone. It is located at the upper thoracic region on the dorsal surface of the ribcage.
Cranium It is the part of the skull that encloses the brain. They have immovable fibrous joint.

Sternum It is the flat bone located in the middle of chest. Also referred as breastbone.

Vertebral column It is a series of approximately 33 bones called vertebrae. They have cartilaginous type joints designed for weight bearing.

17 Select the incorrectly matched pair from following. [NEET (Oct.) 2020]

- (a) Chondrocytes–Smooth muscle cells
- (b) Neurons–Nerve cells
- (c) Fibroblast–Areolar tissue
- (d) Osteocytes–Bone cells

Ans. (a)

The incorrectly match pair is option (a). It can be corrected as
Chondrocytes are cartilage cells. The intercellular material of cartilage is solid, pliable and resists compression. Cells of this tissue are called chondrocytes which are enclosed in small cavities within the matrix secreted by them.

18 Match the following columns and select the correct option. [NEET (Sep.) 2020]

| Column I | Column II |
|-------------------|--|
| A. Floating ribs | 1. Located between second and seventh ribs |
| B. Acromion | 2. Head of the humerus |
| C. Scapula | 3. Clavicle |
| D. Glenoid cavity | 4. Do not connect with the sternum |

- | | | | | |
|-----|---|---|---|---|
| | A | B | C | D |
| (a) | 1 | 3 | 2 | 4 |
| (b) | 3 | 2 | 4 | 1 |
| (c) | 4 | 3 | 1 | 2 |
| (d) | 2 | 4 | 1 | 3 |

Ans. (c)

The correct option is (c). It can be explained as follows

11th and 12th pairs of ribs are not connected ventrally with sternum and are therefore, called floating ribs.

Acromion is a flat expanded process of spine of scapula. The lateral end of clavicle articulates with acromion process. Scapula is a flat triangular bone in the dorsal part of the thorax between 2nd and the 7th rib.

Glenoid cavity of scapula articulates with head of the humerus to form the shoulder joint.

19 Select the correct option. [NEET (National) 2019]

- (a) 11th and 12th pairs of ribs are connected to the sternum with the help of hyaline cartilage

- (b) Each rib is a flat thin bone and all the ribs are connected dorsally to the thoracic vertebrae and ventrally to the sternum
- (c) There are seven pairs of vertebrosteral, three pairs of vertebrochondral and two pairs of vertebral ribs
- (d) 8th, 9th and 10th pairs of ribs articulate directly with the sternum

Ans. (c)

The statement that there are seven pairs of vertebrosteral, three pairs of vertebrochondral and two pairs of vertebral ribs is correct.

Rest statements are incorrect. Correct information about the statements is as follows Vertebrosteral ribs are first seven pairs of true ribs which are attached dorsally to thoracic vertebrae and ventrally to the sternum.

Vertebrochondral ribs (8th, 9th, 10th pairs) are false ribs which are not attached to sternum directly. They are attached to the seventh rib with the help of hyaline cartilage.

Vertebral ribs are the last two pairs of floating ribs which are attached to vertebrae dorsally and are not attached ventrally.

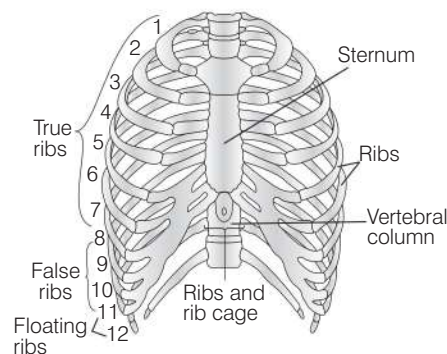
20 Out of 'X' pairs of ribs in humans only 'Y' pairs are true ribs. Select the option that correctly represents values of X and Y and provides their explanation. [NEET 2017]

- (a) X = 12, Y = 7 True ribs are attached dorsally to vertebral column and ventrally to the sternum.
- (b) X = 12, Y = 5 True ribs are attached dorsally to vertebral column and sternum on the two ends.
- (c) X = 24, Y = 7 True ribs are dorsally attached to vertebral column, but are free on ventral side.
- (d) X = 24, Y = 12 True ribs are dorsally attached to vertebral column, but are free on ventral side.

Ans. (a)

In the rib cage, the true ribs are those which are attached to the sternum in the front and vertebral column at back. These are 7 in numbers. Although there are total 12 ribs in the rib cage.

The 11th and 12th ribs are attached to the vertebral column and keep floating in the thoracic cavity, so are called floating ribs.



21 Which of the following is not a function of the skeletal system? [CBSE AIPMT 2015]

- (a) Production of erythrocytes
- (b) Storage of minerals
- (c) Production of body heat
- (d) Locomotion

Ans. (c)

Production of body heat is the function of muscles. The contraction of muscle produce heat, which keeps the body warm during the winters.

22 An acromion process is characteristically found in the [CBSE AIPMT 2005]

- (a) pelvic girdle of mammals
- (b) pectoral girdle of mammals
- (c) skull of frog
- (d) sperm of mammals

Ans. (b)

An acromion process is found in pectoral girdle of mammals. Pectoral girdle consists of scapula and clavicle. The scapula consists of a sharp ridge, the spine and a triangular body. The end of the spine projects as a flattened and expanded process called acromion.

23 What will happen if ligaments are cut or broken? [CBSE AIPMT 2002]

- (a) Bones will move freely at joints
- (b) No movement at joint
- (c) Bone will become unfixed
- (d) Bone will become fixed

Ans. (c)

Ligaments are specialised connective tissues which connect bones together; hence, if they are cut or broken the bone will become unfixed.

24 Which one of the following is a skull bone? [CBSE AIPMT 2000]

- (a) Atlas (b) Coracoid
(c) Arytenoid (d) Pterygoid

Ans. (d)

Pterygoid is a small bone articulated with the palatine. In human it becomes the pterygoid processes of the sphenoid bone.

25 Ligament is a [CBSE AIPMT 1999]

- (a) modified yellow elastic fibrous tissue
(b) inelastic white fibrous tissue
(c) modified white fibrous tissue
(d) None of the above

Ans. (b)

Ligaments are made up of inelastic white fibrous tissue and connect bones at joints. It is also known as articular ligament, articular larua or fibrous ligament.

26 Tendon is made up of [CBSE AIPMT 1999]

- (a) adipose tissue
(b) modified white fibrous tissue
(c) areolar tissue
(d) yellow fibrous connective tissue

Ans. (b)

The modified white fibres tissue form cords called tendons which connect muscles with the bones.

27 Total number of bones in the hind limb of man is [CBSE AIPMT 1998]

- (a) 14 (b) 30
(c) 24 (d) 21

Ans. (b)

1 femur + 1 fibula + 1 tibia + 1 patella + 7 tarsals + 5 meta tarsals + 14 phalanges make one hind limb of man. Total of 30 bones.

28 The lower jaw in mammals is made up of [CBSE AIPMT 1998]

- (a) mandible (b) dentary
(c) maxilla (d) angulars

Ans. (b)

Dentary is tooth bearing membrane bone of lower jaw of the vertebrates-one on each side.

29 The number of floating ribs, in the human body, is [CBSE AIPMT 1995]

- (a) 6 pairs (b) 5 pairs
(c) 3 pairs (d) 2 pairs

Ans. (d)

Usually, there are 12 pairs of ribs, but occasionally these may be 11, 13 or even 14 pairs. The first seven pairs of ribs are known as true ribs.

Pairs 8, 9, 10 are false ribs, they are attached indirectly to sternum by means of cartilages. Last two pairs (11 and 12) do not reach to the sternum and are known as 'floating ribs'.

30 Which is a part of pectoral girdle? [CBSE AIPMT 1994]

- (a) Glenoid cavity (b) Sternum
(c) Ileum (d) Acetabulum

Ans. (a)

A cavity known as glenoid cavity is present at the tip of scapula and coracoid process, for articulation of head of humerus. Pectoral girdle consists of a membranous bone called clavicle and a large replacing bone called shoulder blade or scapula coracoid.

31 Long bones function in [CBSE AIPMT 1993]

- (a) support
(b) support, erythrocyte and leucocyte synthesis
(c) support and erythrocyte synthesis
(d) erythrocyte formation

Ans. (b)

In higher animals, movements and locomotion depend on the association of skeletal muscles and skeletal system (bones and joints). Bones function to provide support as well as produce erythrocytes and leucocytes in the bone marrow.

32 A deltoid ridge occurs in [CBSE AIPMT 1990]

- (a) radius
(b) ulna
(c) femur
(d) humerus

Ans. (d)

Humerus is the bone of forelimb. It bears head, greater tuberosity and lesser tuberosity. Proximal part of humerus bears a slight ridge, which is called as deltoid ridge.

33 Number of cervical vertebrae in camel is [CBSE AIPMT 1990]

- (a) more than that of rabbit
(b) less than that of rabbit
(c) same as that of whale
(d) more than that of horse

Ans. (c)

Cervical vertebrae are seven in number, constant in most of the mammals. Whale, camel, giraffe, etc. have same number of cervical vertebrae. However, long neck in camel and giraffe is due to more length of vertebrae.

34 Extremities of long bones possess cartilage [CBSE AIPMT 1989]

- (a) calcified (b) fibrous
(c) elastic (d) hyaline

Ans. (d)

Hyaline cartilage is the most abundant cartilage. It forms the cushions or pads upon the articular surfaces at joints of long bones, known as articular cartilage.

It forms the costal cartilage at the ventral ends of ribs, and also helps to form the nose, larynx, trachea, bronchi and bronchial tubes.

TOPIC 3 Joints

35 Match the following joints with the bones involved [NEET (Odisha) 2019]

| Column I | | Column II | |
|------------------|-------|--|--|
| 1. Gliding joint | (i) | Between carpal and metacarpal of thumb | |
| 2. Hinge joint | (ii) | Between atlas and axis | |
| 3. Pivot joint | (iii) | Between the carpals | |
| 4. Saddle joint | (iv) | Between humerus and ulna | |

Select the correct option from the following

- 1 2 3 4
(a) (iii) (iv) (ii) (i)
(b) (iv) (i) (ii) (iii)
(c) (iv) (ii) (iii) (i)
(d) (i) (iii) (ii) (iv)

Ans. (a)

The correct matches are

- Gliding joint-(iii) Between the carpals
- Hinge joint - (iv) Between humerus and ulna
- Pivot joint - (ii) Between atlas and axis
- Saddle joint -(i) Between carpal and metacarpal of thumb

36 The pivot joint between atlas and axis is a type of [NEET 2017]

- (a) fibrous joint (b) cartilaginous joint
(c) synovial joint (d) saddle joint

Ans. (c)

The joint between atlas and axis is a type of synovial joint. A considerable movement is allowed at all synovial joints. They are surrounded by tubular articular capsule. The capsule consists of two layers, i.e. outer fibrous capsule and inner synovial membrane, which secretes synovial fluid lubricates and providing nourishment to articular cartilage.

Concept Enhancer

Fibrous joint They do not allow movement because the bones are held firmly by bundles of white fibrous tissue. e.g. joint between the bones of skull.

Cartilaginous joints They allow slight movement; because of the elastic pads of fibrocartilage present between the ends of the bones taking part in the joints, e.g. pubic symphysis of pubis.

Saddle joints This is the type of synovial joints. This type of joint is like ball and socket joint, but not developed fully, e.g. joint between carpal of hand.

37 Which of the following joints would allow no movement? [CBSE AIPMT 2015]

- (a) Fibrous joint
(b) Cartilaginous joint
(c) Synovial joint
(d) Ball and socket joint

Ans. (a)

Fibrous joints are immovable joints that occur between the bones of the cranium and in the tooth sockets. They do not allow movement because the bones are held firmly together by bundles of strong white collagen fibres. The immovable joints are often known as the sutures. The periosteum that covers the bones dips between them as a septum.

38 Select the correct matching of the type of the joint with the example in human skeletal system [CBSE AIPMT 2014]

| Types of Joint | Example |
|-------------------------|---|
| (a) Cartilaginous joint | Between frontal and parietal |
| (b) Pivot joint | Between third and fourth cervical vertebrae |

| | |
|-------------------|-------------------------------------|
| (c) Hinge joint | Between humerus and pectoral girdle |
| (d) Gliding joint | Between carpals |

Ans. (d)

Gliding joint is a type of synovial joint, found between carpal bones and tarsal bones.

Cartilaginous joint between surfaces of skull bones. Pivot joint is found between the atlas and axis. Hinge joint is found in elbow, knee ankle and interphalangeal joints.

39 The characteristics and an example of a synovial joint in humans is [NEET 2013]

| | Characteristics | Examples |
|-----|--|-------------------------------|
| (a) | Fluid cartilage between two bones, limited movements | Knee joints |
| (b) | Fluid filled between two joints, provides cushion | Skull bones |
| (c) | Fluid filled synovial cavity between two bones | Joint between atlas and axis |
| (d) | Lymph filled between two bones, limited movement | Gliding joint between carpals |

Ans. (c)

Joint between atlas and axis is pivot joint, which is an example of synovial joint characterised by the presence of a fluid-filled synovial cavity between the articulating surface of the two bones.

Knee joint (hinge joint) is a synovial joint characterised by the presence of fluid filled synovial cavity between the articulating surfaces of the two bones.

Fluid cartilage between two bones having limited movements is slightly movable joint.

In freely movable joints fluid filled between two joints provides cushion. In gliding joint, the articulating bones can slide upon one another.

40 Elbow joint is an example of [CBSE AIPMT 2009]

- (a) pivot joint
(b) hinge joint
(c) gliding joint
(d) ball and socket joint

Ans. (b)

In hinge joint, the convex surface of one bone fits into the concave surface of another bone, e.g. knee, elbow and interphalangeal joints.

Pivot joint, one bone is fixed and second articulated, e.g. atlas and axial of skull rotate with axis vertebra.

Gliding joints primarily permit side-by-side and back-and-forth gliding movements, e.g. intercarpal joints and intertarsal joints.

In ball and socket joint, ball of one bone articulates in socket of another bone, e.g. head of humerus and glenoid cavity of pectoral girdle.

41 Which of the following pairs, is correctly matched?

[CBSE AIPMT 2005]

- (a) Hinge joint — Between vertebrae
(b) Gliding joint — Between zygapophyses of the successive vertebrae
(c) Cartilaginous joint — Skull bones
(d) Fibrous joint — Between phalanges

Ans. (b)

Gliding joint is present between zygapophyses of the successive vertebrae. This joint permits sliding movements of two bones over each other.

42 The joint found between sternum and the ribs in humans is

[CBSE AIPMT 2000]

- (a) angular joint (b) fibrous joint
(c) cartilaginous joint (d) gliding joint

Ans. (c)

Cartilaginous joints are found between the centra of vertebrae; at pubic symphysis and between ribs and sternum.

Fibrous joints are also called as sutures or immovable joints because in these joints the adjoining bones cannot move upon each other, e.g. coronal suture between frontal and parietal bones of skull. In gliding joints, two bones can slide upon each other, e.g. joints between carpals in wrist.

In angular joints one bone is movable on another bone in two planes side to side and back and forth, e.g. wrist joints.

TOPIC 4

Disorders of Bones and Muscles

- 43** Chronic auto immune disorder affecting neuro muscular junction leading to fatigue, weakening and paralysis of skeletal muscle is called as [NEET 2021]

(a) arthritis
(b) muscular dystrophy
(c) myasthenia gravis
(d) gout

Ans. (c)

Myasthenia gravis is defined as an autoimmune neuromuscular disorder that leads to fluctuating muscle weakness and fatigue. The cause of this disease is circulating antibodies that will block acetylcholine receptors at the post-synaptic neuromuscular junctions.

Other options can be explained as :

Muscular dystrophy is a disease characterised by progressive degeneration of muscle fibres without the involvement of nervous system.

Gout is caused by two conditions that includes one which occur due to excessive formation of uric acid and another by the inability to excrete it. Uric acid deposits in the form of monosodium salts. Arthritis is the swelling and tenderness of one or more number of joints. It is caused by injury, abnormal metabolism, and genetic makeup.

- 44** Match the following columns and select the correct option from the codes given below.

[NEET (Oct.) 2020]

| Column I | Column II |
|-----------------------|---|
| A. Gout | 1. Decreased levels of estrogen |
| B. Osteoporosis | 2. Low Ca^{2+} ions in the blood |
| C. Tetany | 3. Accumulation of uric acid crystals |
| D. Muscular dystrophy | 4. Autoimmune disorder |

Codes

| | | | | |
|-----|---|---|---|---|
| | A | B | C | D |
| (a) | 2 | 1 | 3 | 4 |
| (b) | 3 | 1 | 2 | 4 |
| (c) | 4 | 3 | 1 | 2 |
| (d) | 1 | 2 | 3 | 4 |

Ans. (b)

The option (b) is correct match which is as follows

Gout is inflammation of joints due to accumulation of uric acid crystals.

Osteoporosis occurs due to decreased levels of oestrogen in females. It is an age-related disorder characterised by decreased bone mass and increased chances of fractures.

Tetany is rapid spasms (wild contractions) in muscle when there is low Ca^{2+} ions in the blood.

Muscular dystrophy is progressive degeneration of skeletal muscle mostly due to genetic disorder.

- 45** Which of the following muscular disorders is inherited?

[NEET (National) 2019]

(a) Muscular dystrophy
(b) Myasthenia gravis
(c) Botulism
(d) Tetany

Ans. (a)

Muscular dystrophy is an inherited muscular disorder in which the skeletal muscles degenerate progressively. It is caused due to the absence of dystrophin protein which helps to keep muscle cells intact.

Myasthenia gravis is an autoimmune neuromuscular disease that causes paralysis of skeletal muscles.

Botulism is a type of food poisoning caused by bacterium *Clostridium botulinum*.

Tetany is an involuntary muscle contraction caused due to the low level of calcium in body.

- 46** Osteoporosis, an age-related disease of skeletal system, may occur due to [NEET 2016, Phase II]

(a) immune disorder affecting neuromuscular junction leading to fatigue
(b) high concentration of Ca^{++} and Na^{+}
(c) decreased level of oestrogen
(d) accumulation of uric acid leading to inflammation of joints

Ans. (c)

Osteoporosis is caused by decreased level of oestrogen. Oestrogen deficiency causes both the early and late forms of osteoporosis in post-menopausal women.

Osteoporosis is thinning or weakening of bones which makes them fragile and more likely to break.

Women have low oestrogen level when they are transitioning through menopause. Hence, option (c) is correct.

- 47** Select the correct statement with respect to locomotion in humans.

[NEET 2013]

(a) A decreased level of progesterone causes osteoporosis in old people
(b) Accumulation of uric acid crystals in joints causes their inflammation
(c) The vertebral column has 10 thoracic vertebrae
(d) The joint between adjacent vertebrae is a fibrous joint

Ans. (b)

Inflammation of joints due to the accumulation of uric acid crystals is gout. Fibrous joints are formed by the flat skull bones, which fuse end-to-end with the help of dense fibrous connective tissues in the form of sutures to form cranium. The vertebral column is formed by 26 serially arranged units called vertebrae. The less secretion of progesterone causes abortion as it basically supports pregnancy.

- 48** Select the correct statement regarding the specific disorder of muscular or skeletal system.

[CBSE AIPMT 2012]

(a) Muscular dystrophy –Age related shortening of muscles
(b) Osteoporosis –Decrease in bone mass and higher chances of fractures with advancing age
(c) Myasthenia gravis –Autoimmune disorder which inhibits sliding of myosin filaments
(d) Gout–Inflammation of joints due to extra deposition of calcium

Ans. (b)

Osteoporosis is age related disease in which bones loose minerals and fibres from the matrix causing decreased bone mass and higher chances of fractures with advancing age.

Major causative factors of osteoporosis are imbalance of hormones like calcitonin of thyroid, parathormone of parathyroids, sex hormones and deficiencies of calcium and vitamins.

The disease may be classified as primary type 1, primary type 2 or secondary.

The form of osteoporosis most common in women after menopause is referred to as primary type 1 or postmenopausal osteoporosis.

Secondary osteoporosis may arise at any age and affect men and women equally.